

CASE STUDY

Open Access

Third degree formic acid chemical burn in the treatment of a hand wart: a case report and review of the literature

Nicolas Balagué*, Philippe Vostrel, Jean-Yves Beaulieu and Jan van Aaken

Abstract

Objective: Cutaneous warts are very common and a large variety of topical treatments and drugs can be employed to cure these skin injuries that can arise on any part of the body. But are these products really safe?

Method: We performed a case description and PubMed literature review using key words "wart," "chemical burn," and "formic acid." All articles in English and French were selected.

Results: This is the first report of a chemical burn by formic acid in the treatment of warts. Numerous topical treatments for cutaneous warts are available with many new drugs appearing every year. However, only a few treatments have proven their effectiveness, such as salicylic acid or cryotherapy with liquid nitrogen that are commonly used. Moreover, most cutaneous warts will resolve spontaneously without any treatment and several products, including topical acids and cryotherapy devices, presented adverse effects such as chemical burns or frostbites so demonstrating that even frequently used treatments can be harmful.

Conclusion: Topical treatments used for wart removal are not without risk even if some products are sold without prescription. For self-treatment products, we recommend enhanced warning by the pharmacist about the risks involved.

Keywords: Wart; Chemical burn; Formic acid

Case presentation

A 58 year-old man in good health presented with a wart on the volar surface of the long finger of his left hand for eight months. A dermatologist recommended a new ointment containing formic acid (FA), accessible without medical prescription and authorized for use in children. This topical chemical agent was to be applied on the wart with a cotton bud, two to three times during the first week of treatment and then once a week until complete disappearance of the wart.

Unfortunately the patient did not read the enclosed notice and applied the product to the wart for six continuous hours during the night with use of an occlusive dressing. He was awoken during the night by pain and removed the ointment. In the morning he noted a non-painful skin lesion and two days later presented to the

emergency department of our hospital. He had a third degree chemical burn of the ulnar volar side of the first phalanx of the long finger with loss of sensibility on this side of the digit. This lesion presented as a dry skin necrosis of 1.8 cm in diameter with peripheral inflammation without signs of infection (Figure 1). Two point discrimination of the ulnar side of the fingertip couldn't be perceived (>14 mm).

Under local anesthesia the entire skin thickness along with part of the subcutaneous tissue was excised and the wound left to undergo controlled scarring (Figure 2). During the next weeks the wound became atonic in its center and epithelialization started at the periphery. A flexion contracture of approximately 20° of the proximal interphalangeal (PIP) joint was observed during the scarring process. A second debridement of the subcutaneous tissue was done. The digital canal was intact but the ulnar collateral nerve was found to be exposed. Granulation was then observed during the next few days, and

* Correspondence: nbalague@hotmail.com
Service of Orthopedic Surgery, Unit of Hand Surgery University Hospitals of Geneva, Geneva, Switzerland

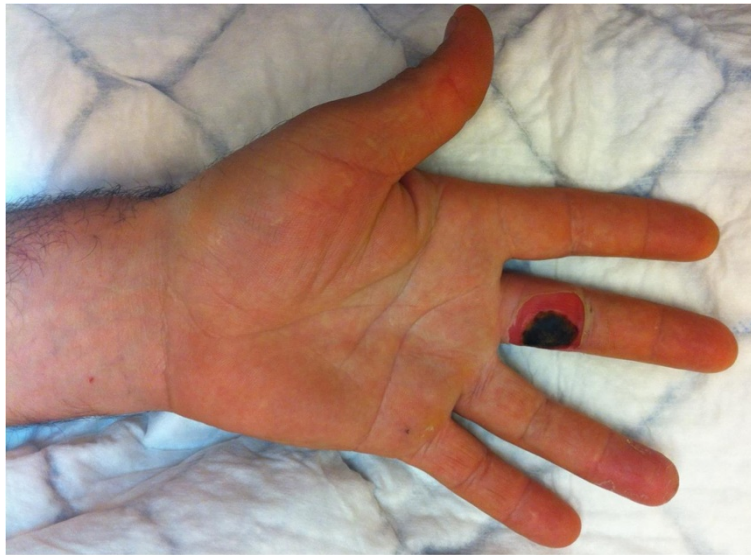

Figure 1 Initial appearance of the finger with skin necrosis corresponding to a third degree chemical burn.

the wound was closed after 58 days of controlled scarring (Figure 3). We decided against skin grafting to improve the aesthetic result and the wound appeared not deep enough to consider a local flap. Complete extension of the PIP joint recovered with use of a 3-point digital splint. Sensibility remained impaired at a 6 month follow-up, with neuropathic pain (tingling, stiffness, numbness) according to the pain questionnaire of Saint-Antoine (French equivalent of the McGill pain questionnaire from Melzack) (Melzack 1975). The assessment of axonal injury was positive: Pressure threshold 1.5 g, 2 point

discrimination test 18 mm (normal 2 mm), and vibration threshold 0.220 mm (normal 0.010 mm) (Figure 4).

Discussion

To the best of our knowledge this is the first report in the literature of a third degree (Devgan et al. 2006) chemical burn of a finger after topical treatment of warts with an ointment containing formic acid.

Warts are caused by some species of human papillomavirus (HPV) and affect adults and children (Lebwohl et al. 2010). They are contagious and usually enter the

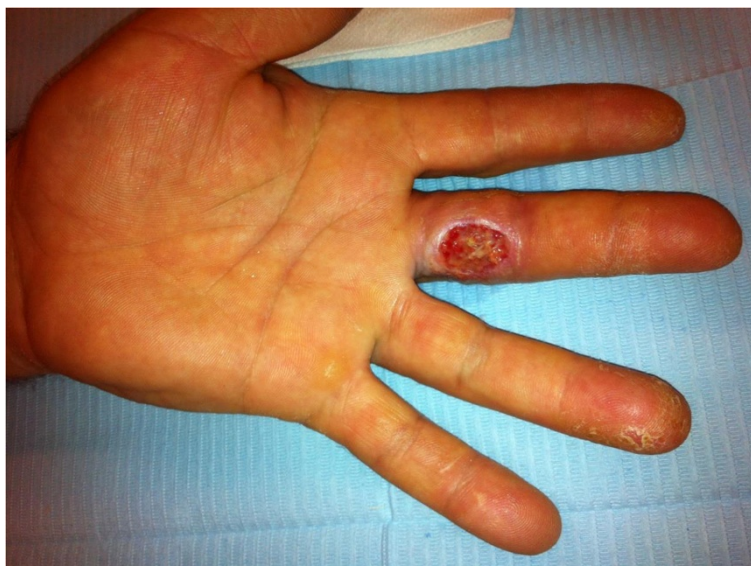

Figure 2 Appearance of the finger after full thickness skin debridement.

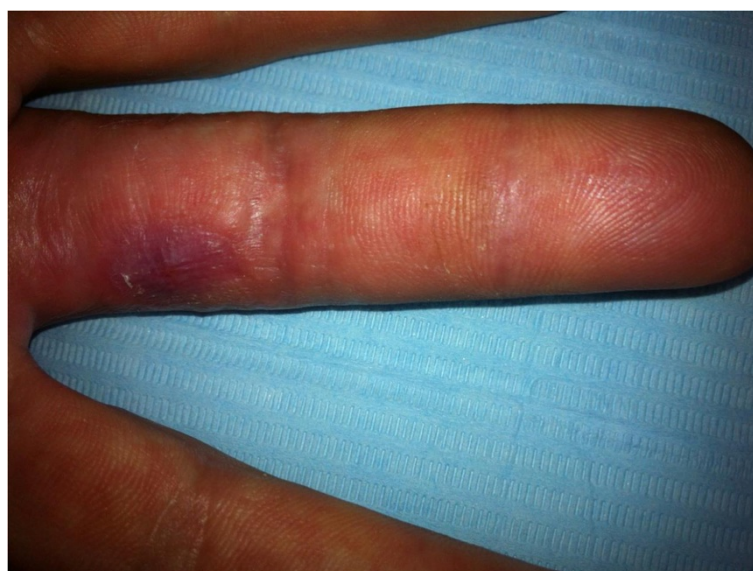

Figure 3 Appearance of the finger after complete healing.

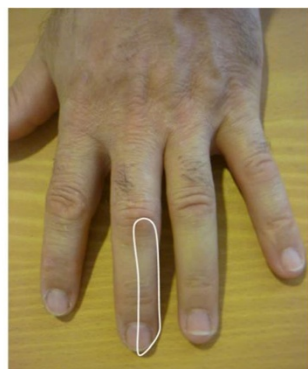body through an area of broken skin. They typically occur on the hands and feet, but can appear on any part of the body including face, nails and genitals. Warts often disappear spontaneously after a few months but may last for years and can recur (Micali et al. 2004).

Many products have been tried in the treatment of warts. Often topical application of concentrated salicylic acid or cryotherapy (with liquid nitrogen or carbon dioxide) are used (Bruggink et al. 2010; Bacelieri and Johnson 2005; Gibbs and Harvey 2006; Gibbs et al. 2002; Kwok et al. 2011). Other topical acids include monochloroacetic acid, bichloroacetic acid, trichloroacetic acid, lactic acid and formic acid (Gibbs and Harvey 2006; Bhat et al. 2001). Additional therapies include imiquimod, fluorouracil or topical zinc sulfate (Micali et al. 2004; Batista et al. 2010; Khattar et al. 2007). Even systemic

therapy has been proposed with the use of cimetidine or levamisole (Simonart and de Maertelaer 2012). Surgical curettage and pulsed-dye or carbon dioxide laser have also be proposed (Park and Choi 2008). However, the majority of these treatments have not definitively proven their effectiveness.

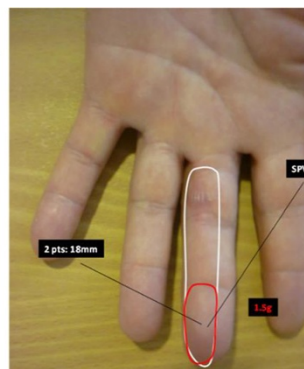
The use of topical acid or cryotherapy for wart removal is not without risk. Cryotherapy devices have been incriminated in frostbite injuries (Ramsey et al. 2007; Sammut et al. 2008), and cases of chemical burn after use of salicylic acid and monochloroacetic acid have been described (Chapman et al. 2006; Tiong and Kelly 2009). Some of the chemical burns were limited to full-thickness skin, but others showed deeper lesions such as tendon rupture (Yates et al. 1988), injuries to the germinal nail matrix, and complete destruction of the growing

Esthesiography
0.4g



Dorsal branch of the palmo-ulnar collateral nerve from long finger

Esthesiography
0.2g



Palmo-ulnar collateral nerve from long finger

Figure 4 Sensitivity assessment of the finger at 6 months.

cartilage (Baser et al. 2008). These cases of deeper injuries were found in children between 10 and 14 years of age.

Formic acid, also called methanoic acid, is found in nature in the venom of ants. It is industrially produced for many uses such as for food preservation since it is antibacterial, for textile production, in some cleaning products, and as a pesticide. In the human body FA is produced from methanol that we ingest, inhale or produce. FA has low toxicity (it is used as a food additive), but when concentrated it is corrosive to biological tissue. This property explains how it is used in the treatment of warts, but can lead to a chemical burn. Direct eye contact with liquid or vapor containing FA can also lead to blindness. It also has a systemic toxicity that can cause acidosis and lead to optic nerve damage and blindness. Furthermore, FA can lead to memory loss, confusion, seizure, coma and cardiac arrest. Chronic exposure may cause kidney or liver damage and skin allergy (Liesivuori and Savolainen 1991).

This case demonstrates that the ability to obtain drugs without medical prescription can cause harm by inappropriate use. In this case the topical application was strictly limited to the surface of the wart, but the duration of the application was not respected since our patient applied the product for 6 hours continuously. A full thickness skin lesion with persistent damage to the underlying collateral ulnar digital nerve resulted, with long lasting loss of ulnar side sensibility of the digit.

Consent

Informed consent was obtained from the patient for the publication of this report and any accompanying images.

Abbreviation

FA: Formic acid.

Competing interests

The authors report no conflict of interest concerning the materials or methods used in this study or the findings specified in this paper.

Authors' contributions

NB was part of the surgical team caring for the patient, and participated in drafting the manuscript. PV was part of the surgical team caring for the patient and reviewed the manuscript. JYB was the senior surgeon of the surgical team and reviewed the manuscript. JVA was responsible for case recruitment, and participated in the drafting and editing of the manuscript. All authors read and approved the final manuscript.

Acknowledgement

We thank Dr Richard Stern from the University Hospital of Geneva for assistance in the preparation of the manuscript.

Received: 27 January 2014 Accepted: 23 July 2014

Published: 5 August 2014

References

Bacelieri R, Johnson SM (2005) Cutaneous warts: an evidence-based approach to therapy. *Am Fam Physician* 72:647–652

- Baser NT, Yalaz B, Yilmaz AC, Tuncali D, Aslan G (2008) An unusual and serious complication of topical wart treatment with monochloroacetic acid. *Int J Dermatol* 47(12):1295–1297
- Batista CS, Atallah AN, Saconato H, da Silva EM (2010) 5-FU for genital warts in non-immunocompromised individuals. *Cochrane Database Syst Rev* 14(4):CD006562
- Bhat RM, Vidya K, Kamath G (2001) Topical formic acid puncture technique for the treatment of common warts. *Int J Dermatol* 40(6):415–419
- Bruggink SC, Gussekloo J, Berger MY, Zaaijer K, Assendelft WJJ, de Waal MWM, Bavink JN, Koes BW, Eekhof JA (2010) Cryotherapy with liquid nitrogen versus topical salicylic acid application for cutaneous warts in primary care: randomized controlled trial. *CMAJ* 182:1624–1630
- Chapman T, Mahadevan D, Mahajan A, Perez-Temprano A, McDiarmid J (2006) Iatrogenic full-thickness chemical burns from monochloroacetic acid. *J Burn Care Res* 27(4):545–547
- Devgan L, Bhat S, Aylward S, Spence RJ (2006) Modalities for the assessment of burn wound depth. *J Burns Wounds* 5:e2
- Gibbs S, Harvey I (2006) Topical treatments for cutaneous warts. *Cochrane Database Syst Rev* 3:CD001781
- Gibbs S, Harvey I, Sterling J, Stark R (2002) Local treatments for cutaneous warts: systematic review. *BMJ* 325:461
- Khattar JA, Musharrafieh UM, Tamim H, Hamadeh GN (2007) Topical zinc oxide vs. salicylic acid-lactic acid combination in the treatment of warts. *Int J Dermatol* 46:427–430
- Kwok CS, Holland R, Gibbs S (2011) Efficacy of topical treatments for cutaneous warts: a meta-analysis and pooled analysis of randomized controlled trials. *Br J Dermatol* 165:233–246
- Lebwohl MG, Rosen T, Stockfleth E (2010) The role of human papillomavirus in common skin conditions: current viewpoints and therapeutic options. *Cutis* 86(suppl 1–suppl 11, quiz suppl 12
- Liesivuori J, Savolainen H (1991) Methanol and formic acid toxicity: biochemical mechanisms. *Pharmacol Toxicol* 69:157–163
- Melzack R (1975) The McGill Pain Questionnaire: major properties and scoring methods. *Pain* 1:277–299
- Micali G, Dall'Oglio F, Nasca MR, Tedeschi A (2004) Management of cutaneous warts: an evidence-based approach. *Am J Clin Dermatol* 5:311–317
- Park HS, Choi WS (2008) Pulsed dye laser treatment for viral warts: a study of 120 patients. *J Dermatol* 35:491–498
- Ramsey K, Ragan C, Dheansa B (2007) Adverse effects of over the counter cryotherapy. *Burns* 33(4):533–534
- Sammot SJ, Brackley PT, Duncan C, Kelly M, Raraty C, Graham K (2008) Frostbite following use of a commercially available cryotherapy device for the removal of viral warts. *Dermatol Online J* 14(6):9
- Simonart T, de Maertelaer V (2012) Systemic treatments for cutaneous warts: A systematic review. *J Dermatolog Treat* 23(1):72–77
- Tiong WH, Kelly EJ (2009) Salicylic acid burn induced by wart remover: a report of two cases. *Burns* 35(1):139–140
- Yates VM, Scott MM, Carter ED (1988) Rupture of tendon after cryotherapy for hand wart. *BMJ* 297(6656):1106

doi:10.1186/2193-1801-3-408

Cite this article as: Balagué et al.: Third degree formic acid chemical burn in the treatment of a hand wart: a case report and review of the literature. *SpringerPlus* 2014 **3**:408.

Submit your manuscript to a SpringerOpen[®] journal and benefit from:

- Convenient online submission
- Rigorous peer review
- Immediate publication on acceptance
- Open access: articles freely available online
- High visibility within the field
- Retaining the copyright to your article

Submit your next manuscript at ► springeropen.com